

DIAGNOSTIC SIGNIFICANCE OF RADIOLOGICAL SIGNS OF TARSALE COALITIONS

Ibragimova Iroda Vakhidovna,
assistant of the department of medical radiology, ASMI

Abstract. Tarsal coalition is an abnormal fusion of two or more tarsal bones, which can lead to foot deformities, pain syndrome, and damage to the ligaments of the ankle joint. Radiological diagnostics of tarsal coalitions is difficult, since most radiological signs only indirectly indicate its presence. The aim of the study is to determine the diagnostic significance of indirect radiological signs of tarsal coalitions in children.

Keywords: tarsal coalition, radiological diagnostics.

INTRODUCTION

Tarsal coalitions are a foot malformation characterized by the fusion of two or more tarsal bones. According to most authors, the incidence of tarsal coalitions is 1–2% [1]. However, due to the widespread development of imaging techniques, publications have emerged that reflect a higher incidence (up to 13–14%) of this pathology in the population [2]. Tarsal coalitions are characterized by a change in the shape of the tarsal bones, narrowing or intermittent movement of the joint spaces, secondary deformation, and arthrosis in the joints of the foot.

MATERIALS AND METHODS

The main method of diagnosing tarsal coalitions when patients first seek medical attention is radiography of the feet in standard projections: direct, lateral, and with the patient standing [4]. If necessary, to clarify the diagnosis, the study is performed in additional special projections. Direct methods of visualizing coalitions are used to confirm the diagnosis - computed tomography and magnetic resonance imaging [3]. The presence of tarsal coalitions and their forms are indicated by direct and indirect radiographic signs. Direct radiographic signs include the presence of a distinct zone of pathological fusion of the tarsal bones on the radiograph [4]. However, in most cases, the presence of a tarsal coalition must be judged by indirect radiographic signs. By rigid forms we meant planovalgus foot deformities, which were clinically accompanied by limited range of motion in the ankle and/or subtalar joints. Of these, there were 36 boys and 26 girls. The patients' ages ranged from 10 to 17 years. All patients underwent standard radiography of the feet in direct and lateral projections and computed tomography of the feet. In computed tomography, 15 patients (26 feet) were found to have calcaneonavicular coalitions, 10 patients (18 feet) had talocalcaneal coalitions; tarsal coalitions were excluded from 37 patients.

RESULTS AND DISCUSSION

When performing standard radiography of 26 feet with calcaneonavicular coalition, the "anteater nose" symptom (elongated anterior process of the calcaneus) was determined in 24 cases on the radiographs in the lateral projection. Of these, the fusion zone of the calcaneus and navicular bones was directly visualized in 18 cases (Fig. 1).

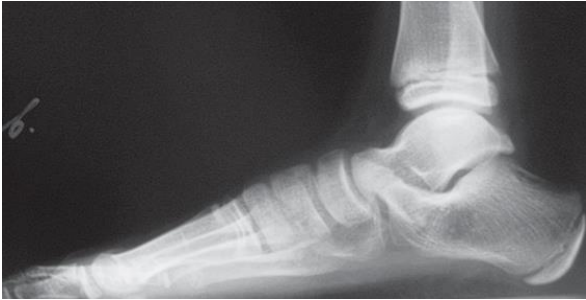

Fig. 1. Patient M., 12 years old. X-ray of the left foot in lateral projection: calcaneonavicular coalition; positive "anteater nose" symptom; the fusion site of the calcaneus and navicular bones is visualized

In 8 patients with fibrous forms of calcaneonavicular coalitions (including those with the "anteater nose" symptom), the fusion zone of the bones was not visualized. The frequency of the "anteater nose" symptom in the study groups is presented in Table 1.

Table 1

Frequency of occurrence of the symptom "anteater nose" in the study groups

X-ray examination	Calcaneonavicular coalition (+)	Calcaneonavicular coalition (-)	Total
Sign (+)	24	5	29
Sign (-)	2	83	85
Amount	26	88	114

Thus, the sensitivity of the "anteater nose" symptom in calcaneonavicular coalitions was 92.3%. In three patients (5 feet), an elongated anterior process of the calcaneus was also noted on the radiographs. When conducting CT in these patients, tarsal coalition was excluded, which made it possible to establish the specificity of this sign equal to 94.31%. In lateral projection radiographs of the feet, in patients with talocalcaneal coalition, the C-symptom was present in 16 cases (Fig. 2).

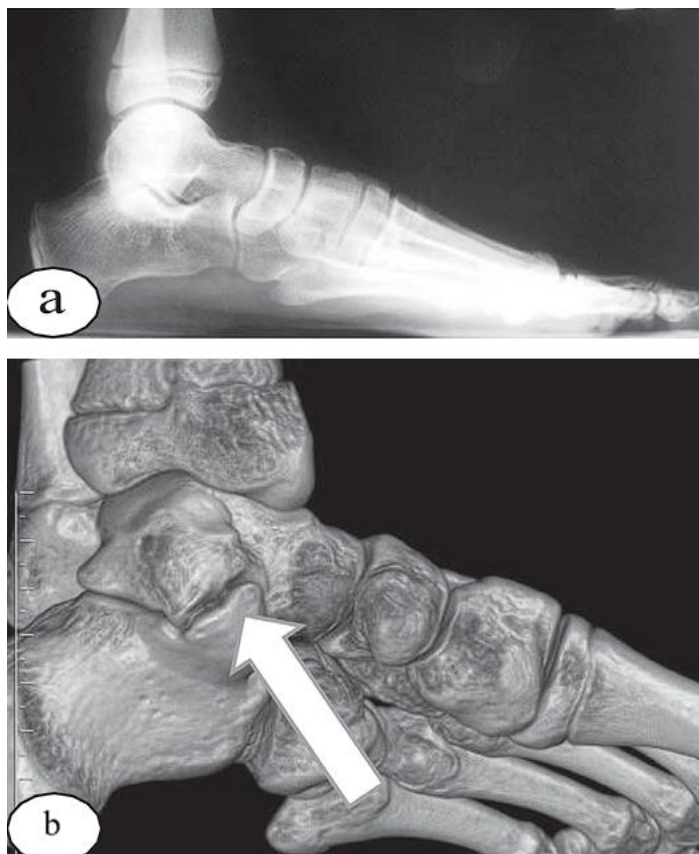


Fig. 2. Results of examination of patient A., 13 years old, with fibrous talocalcaneal coalition on the left: a – X-ray of the left foot in lateral projection: C-symptom is determined; b – CT, SSD-reconstruction of the posterior and middle sections of the left foot – talocalcaneal coalition is verified (arrow)

According to CT data, in 8 patients with talocalcaneal coalition (16 feet), the concrecence zone was localized in the area of the medial facet of the subtalar joint, in 2 patients (2 feet), fusion was noted at the level of the posterior and medial facets.

Thus, according to our study, the C-symptom in talocalcaneal coalitions had a sensitivity of 88.89%. Among patients without talocalcaneal coalition, the C-symptom was noted in 22 cases, the specificity of this symptom was 77.08%. The insufficiently high specificity of this radiographic sign is due to the fact that a positive C-symptom can accompany severe forms of planovalgus foot deformities without tarsal coalitions. The “beak” symptom, unlike the two above-described radiographic signs, has no direct anatomical connection with the fusion zone, therefore, we assessed the sensitivity of this sign as a whole for the group of patients with tarsal coalitions. This symptom was observed in 14 cases in patients with talocalcaneal coalition, whereas in the group of patients with calcaneonavicular coalition the “beak” symptom was detected in only two cases.

Thus, the sensitivity of the sign was 36.36%, the specificity was 97.14%. In three cases, the marginal growths on the radiograph originated not only from the talus, but also from the navicular bone. In the group of patients without tarsal coalitions, this symptom was noted in only two cases. In both cases, these were patients who were involved in professional sports, i.e. the “beak” symptom was most likely a consequence of excessive physical exertion. The “beak” symptom in tarsal coalitions has low sensitivity and significant specificity. Therefore, the presence of this symptom on the radiograph does

THE MULTIDISCIPLINARY JOURNAL OF SCIENCE AND TECHNOLOGY

VOLUME-5, ISSUE-1

not directly indicate the presence of a coalition, but characterizes the functional state of the joints of the middle and rear sections of the foot.

Radiography is the main diagnostic method for tarsal coalitions, so a standard radiographic examination should be performed in all cases where this anomaly is suspected. However, routine radiographic examination does not always allow diagnosing tarsal coalition. The main difficulties in analyzing radiographs of feet with talocalcaneal coalitions are associated with the complexity of visualizing the area of interest, and with calcaneonavicular coalitions - with the complexity of interpreting radiographic data. The results of computed tomography allow us to confirm or exclude the suspected diagnosis. However, computed tomography should be prescribed only if there are justified indications. We assumed that determining the diagnostic significance of indirect radiographic signs of tarsal coalitions will help establish the feasibility of additional studies.

CONCLUSION

1. In X-ray examination of the feet of patients with tarsal coalitions, the "anteater nose" symptom and the C-symptom have high sensitivity and specificity.
2. The most difficult to diagnose are talocalcaneal coalitions. The C-symptom, which often accompanies this type of coalition and has high sensitivity, has average specificity, since it can also occur in the absence of a tarsal coalition. The "beak" symptom, which often accompanies a talocalcaneal coalition, has average sensitivity and high specificity, reflects the severity of functional disorders of the tarsal joints.

REFERENCES

1. Kenis V.M., Nikitina N.V. Tarsal coalitions in children (literature review)]. *Travmatologia i Ortopedia Rossii*. 2020;(3):159-165.
2. Altman D.G., Bland J.M. Diagnostic tests 1: sensitivity and specificity. *BMJ*. 2014;308:15.
3. Bohne W.H. Tarsal coalition. *Curr. Opin. Pediatr.* 2021;13:29-35.
4. Crim J.R., Kjeldsberg K.M. Radiographic diagnosis of tarsal coalitions. *Am. J. Radiol.* 2014;182:323-328.
5. Harris R.I., Beath T. Etiology of peroneal spastic flat foot. *J. Bone Joint Surg.* 2018;30-B(4):624-634.