

**Sharapova Gulnoza Valentinovna**

Teacher at Navoi State Pedagogical Institute

**Boboqulova Dilso'z Zokir qizi**

A student of the 4st stage of biology education

**ABSTRACT.** In this article, the anatomical, physiological and histological structure of the adrenal gland. Connection of kidney and adrenal gland. Fundamental study of the hormones produced by the adrenal gland and their mechanisms of action. Adrenal blood supply and control by the nervous system. Elucidation of the prevention and treatment of these diseases and its benefits.

**Keywords:** Adrenal glands, inferior vena cava, peritoneal sac, mineralocorticoids, hormones, aldosterone, glucocorticoids, adrenal cancer.

Adrenal glands, as the name suggests, are organs located above the kidneys. The most important role of the adrenal glands is the production of hormones that ensure the proper functioning of the body. Adrenal glands are paired endocrine glands and are distinguished by their small size. The name of the adrenal glands indicates their location in the human internal system. Adrenal glands are primarily responsible for the production of hormones necessary for the proper functioning of the body. If the adrenal glands are not working properly, there is a lack of hormones, which can lead to serious health problems and in some cases even death[1].

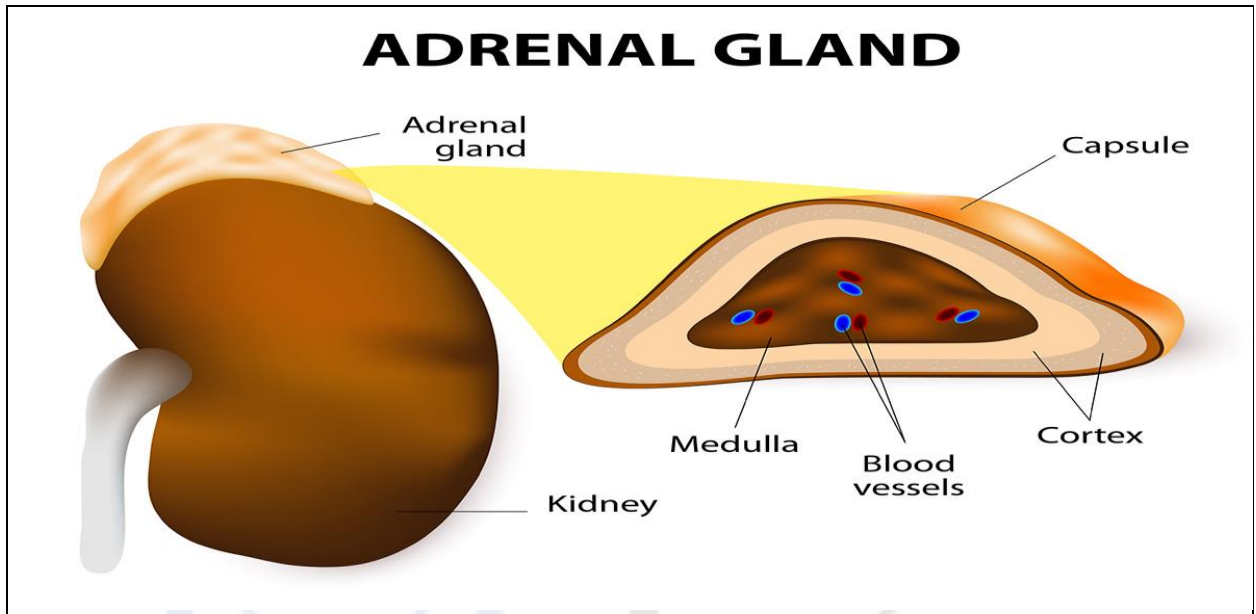
The back surface of the adrenal glands is adjacent to the lumbar part of the diaphragm. In addition to the right adrenal gland, it attaches to the inferior vena cava, peritoneum and liver. On the other hand, the left adrenal gland is adjacent to the peritoneal sac, stomach, pancreas and splenic artery.

Mineralocorticoids are hormones synthesized in the glomerular layer of the cortex of the adrenal glands. Among these hormones, aldosterone, an organic chemical compound from the steroid group, has the strongest effect. Aldosterone is involved in the regulation of water-mineral balance in the body, which means it maintains the correct level of mineral salts and water in the body. This hormone affects the function of the renal tubules by increasing the absorption of sodium salts and limiting their excretion in the urine [3]. Aldosterone also works by reducing the amount of blood that passes through the kidneys, thereby reducing the amount of urine. Aldosterone is also involved in transport processes in the kidneys. In addition, this hormone together with renin and angiotensin regulates blood pressure;

Glucocorticoids are hormones synthesized in the reticular and band layers. The most important and powerful hormone in the group of glucocorticoids is cortisol, also called the stress hormone. A characteristic feature of cortisol is called the circadian rhythm of secretion, so its highest concentration is observed in the morning, and the lowest is observed at midnight. Cortisol has anti-inflammatory properties, so it is a common ingredient in powerful anti-inflammatory drugs. This hormone also affects the level of glucose in the blood and, more precisely, causes an increase in glucose, for example, during stressful moments.

Sex hormones - androgens are produced in small amounts in the band and reticular layers. These hormones accelerate the growth of the body and the formation of secondary male sexual characteristics[2].

The medullary layer of the adrenal gland produces hormones that have a similar effect to the sympathetic nervous system. It differs from other cells of the adrenal gland in that the medullary layer is stained yellow with cellular chromium salts. Such chromophin cells produce adrenaline and its derivatives.



#### The structure of the adrenal gland

Adrenaline is one of the fastest acting hormones. It accelerates blood circulation, strengthens and speeds up the contraction of the heart, improves breathing through the lungs, expands the bronchi, increases the contraction of muscles, increases the breakdown of glycogen in the liver, increases the amount of sugar in the blood, and prevents the muscles from getting tired quickly. All these effects of adrenaline lead to one general result - mobilizing all the body's strength to perform hard work.

The organic connection of the sympathetic nervous system with the chromaffin cells of the adrenal gland ensures that adrenaline is released very quickly in all cases, which is a condition that occurs when a force with a high voltage is required from it very quickly in human life[4].

Diseases that affect the adrenal glands can be divided into:

1. diseases associated with hormone secretion abnormalities;
2. diseases associated with mineralocorticoid secretion disorders;
3. androgen excess diseases;
4. tumors of the adrenal glands;
5. adrenal cancer;
6. pheochromocytoma.

The weight of one adrenal gland of a newborn baby is 8 - 9 g, the dimensions are: 3.3-3.5 cm in diameter, 1.2-1.3 cm in thickness, 2.3 in height. -2.8 cm. In his adrenal gland, the bark substance is good, and the pith substance is poorly developed. In the first three months of a child's life, the weight of the adrenal gland decreases significantly (up to 3.5 g). This decrease in the size of the gland is due to the thinning and regrowth of its bark. The structure of the cortex of the adrenal gland begins to recover after the age of 5 and is completely completed by the age of

11. The weight of the adrenal gland is 4.6 g at 5 years old, 6.6 g at 10 years old, 8.63 g at 15 years old, and reaches 12.95 g at 20 years old [1].

In conclusion, the proper functioning of the adrenal glands is very important for human health. When the adrenal glands are not working properly, there is a change in the level of hormones in the blood - it can be an increase or a decrease.

#### **REFERENCES**

1. A. Ahmedov, O'. Mirsharapov, T. Sagatev, H. Rasulov "Anatomy" Volume II Tashkent -2020
2. Karimova N.A., Kurbanova N.S. Disorders of physical development in adolescents and its complications // Journal of Cardiorespiratory Research. - 2021. -Vol. 2. - No. 2.
3. Teshayev Sh. J., Khasanova DA Macroscopic structure of the rat's Peyer's patches under the small intestine and intestinal changes under the influence of chronic radiation. Operative Surgery and Clinical Anatomy (Pirogov Scientific Journal - 2020, 4 (1), 41-45.
4. Nabiev B.B., Khudoyberdiev D.K. Anatomy of fetal organs of the human lymphoid system (overview of literature sources; Literature review). Science achievements and education, 2020 - B. 16 70.